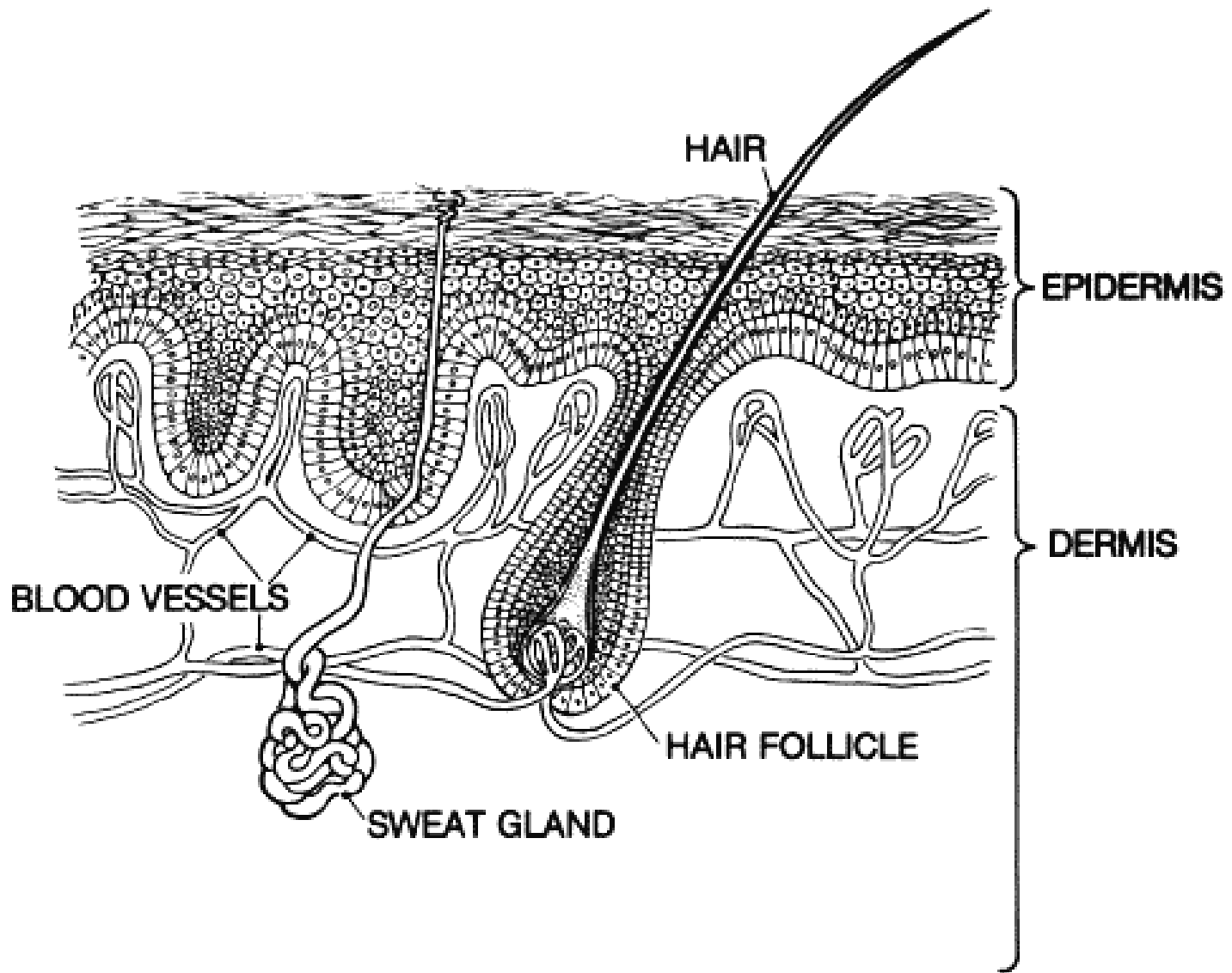


Integumentary System

Integumentary System

- Skin, hair, and nails.
- Skin:
 - Epidermis: outer layer.
 - Dermis: also called corium, or “true skin.”
 - Subcutaneous fascia: innermost layer.



Integumentary Glands



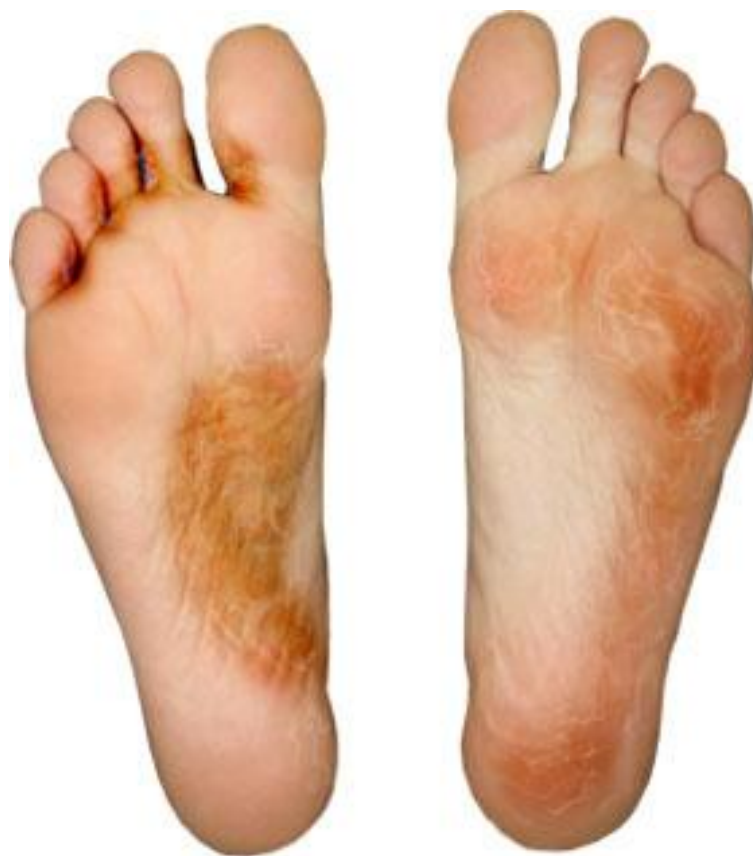- Sudoriferous: sweat glands.
- Sebaceous: oil glands.

Functions

- Protection.
- Sensory Perception.
- Body temperature regulation.
- Storage (temporary storage of fat, glucose, water, vitamins, salts).

Functions

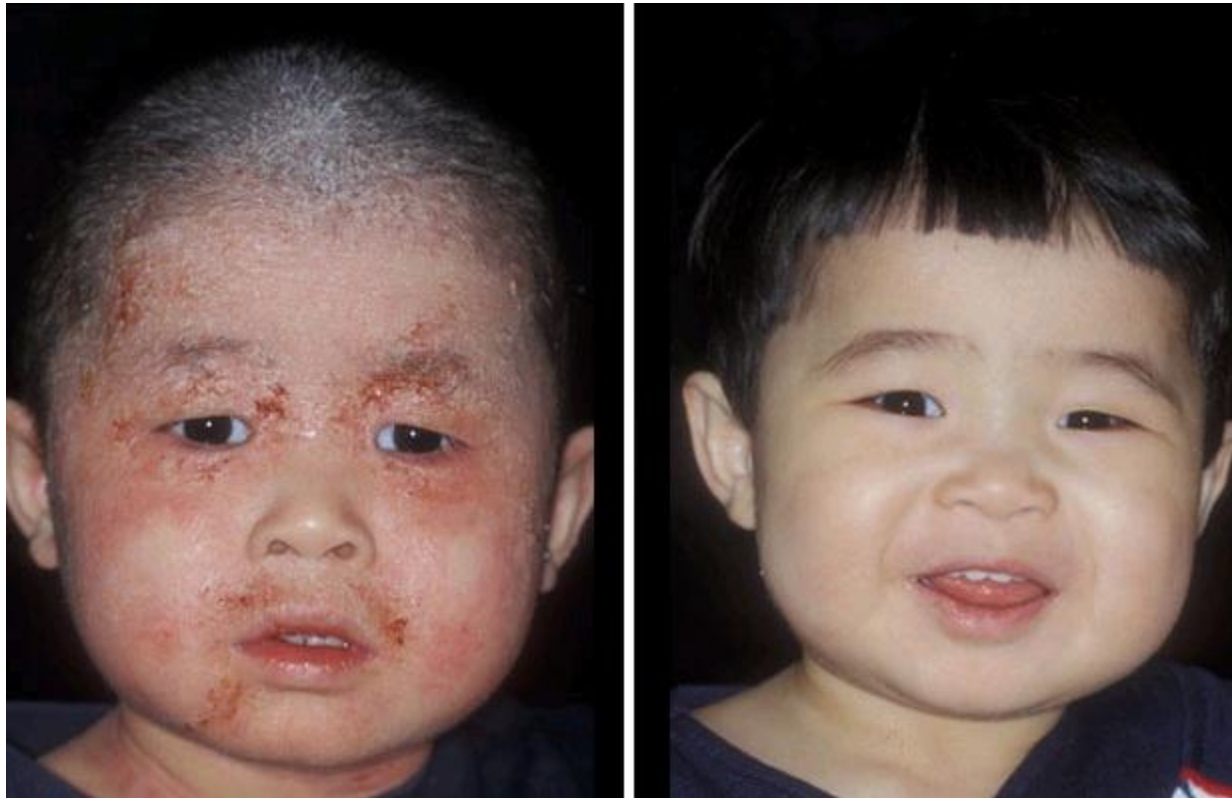- Absorption (medicine).
- Excretion.
- Production (vitamin D).



Athlete's Foot

Athlete's Foot

- Contagious fungal infection.
- Usually affects the feet.
- Itching, blisters, cracking, open sores.
- Treatment: antifungal medication, keeping feet clean and dry.



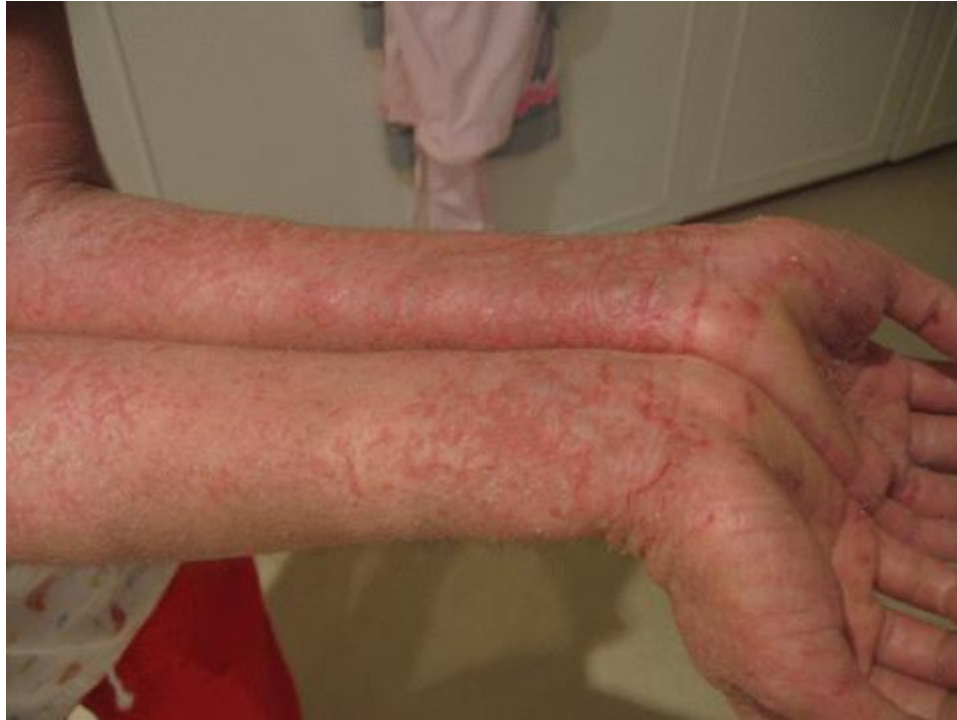Dermatitis
(impetigo)

Dermatitis

- Inflammation of the skin.
- Caused by any substance that irritates the skin.
- Often an allergic reaction to detergents, cosmetics, pollen, or certain foods.

Impetigo

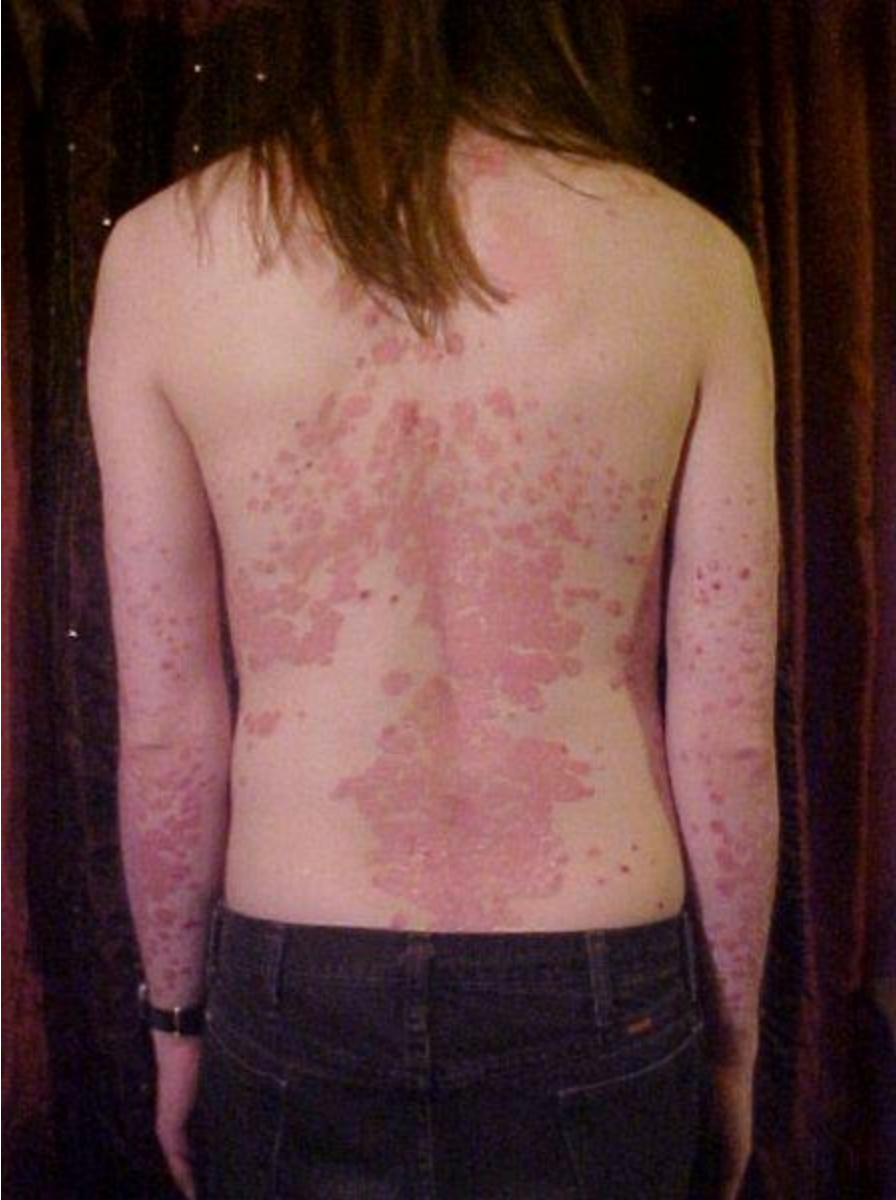- Highly contagious skin infection.
- Usually caused by streptococci or staphylococci organisms.
- Symptoms: erythema, oozing vesicles, pustules, and formation of yellow crust.
- Treatment: antibiotics, keeping lesions clean and dry.



Eczema

Eczema

- Noncontagious.
- Inflammatory skin disorder caused by an allergen or skin irritant.
- Diets, cosmetics, soaps, medications, and emotional stress can be causes.
- Treatment: remove irritant, apply corticosteroids to reduce the inflammatory response.

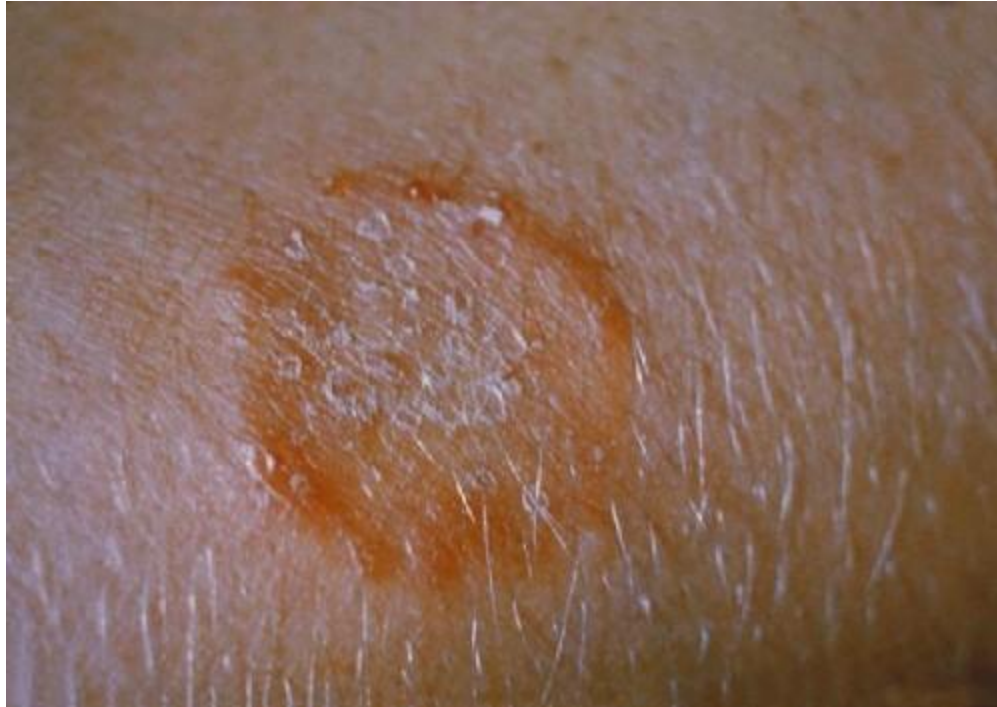

Psoriasis

Psoriasis

- Chronic, noncontagious, inherited skin disease.
- Symptoms: thick, red arease covered w/ white or silver scales.
- No cure.
- Treatment: coal/tar or cortisone ointments, ultraviolet light, and/or scale removal.

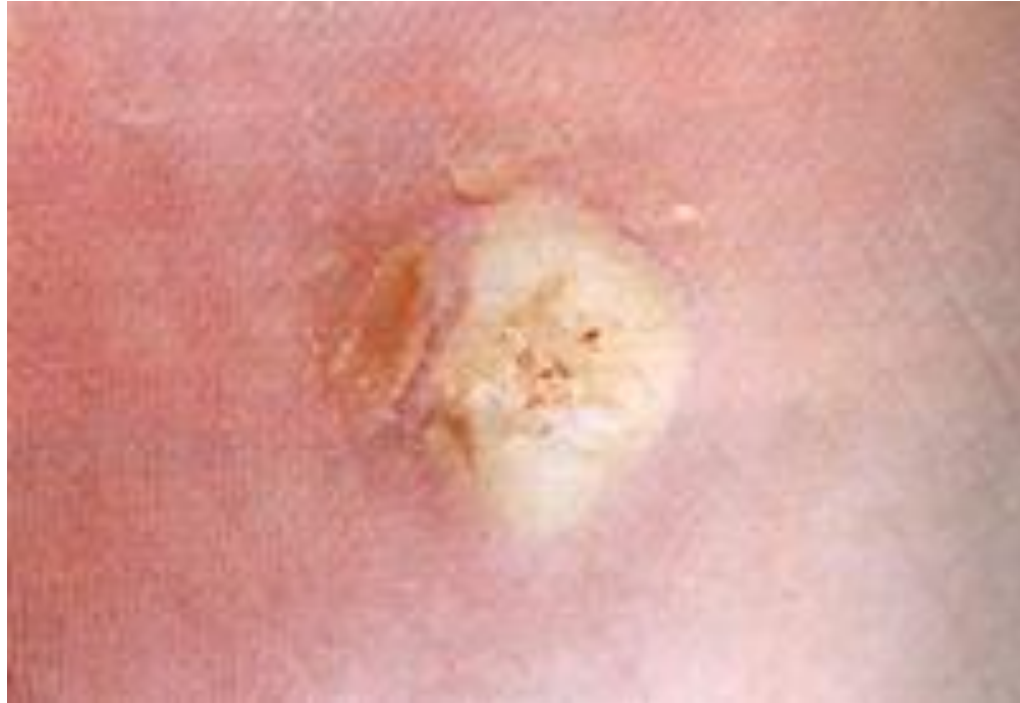Ringworm



Ringworm

- Highly contagious.
- Fungal infection of the skin or scalp.
- Formation of a flat or raised circular area with a clear central area surrounded by an itchy, scaly, or crusty outer ring.
- Treatment: antifungal medications.

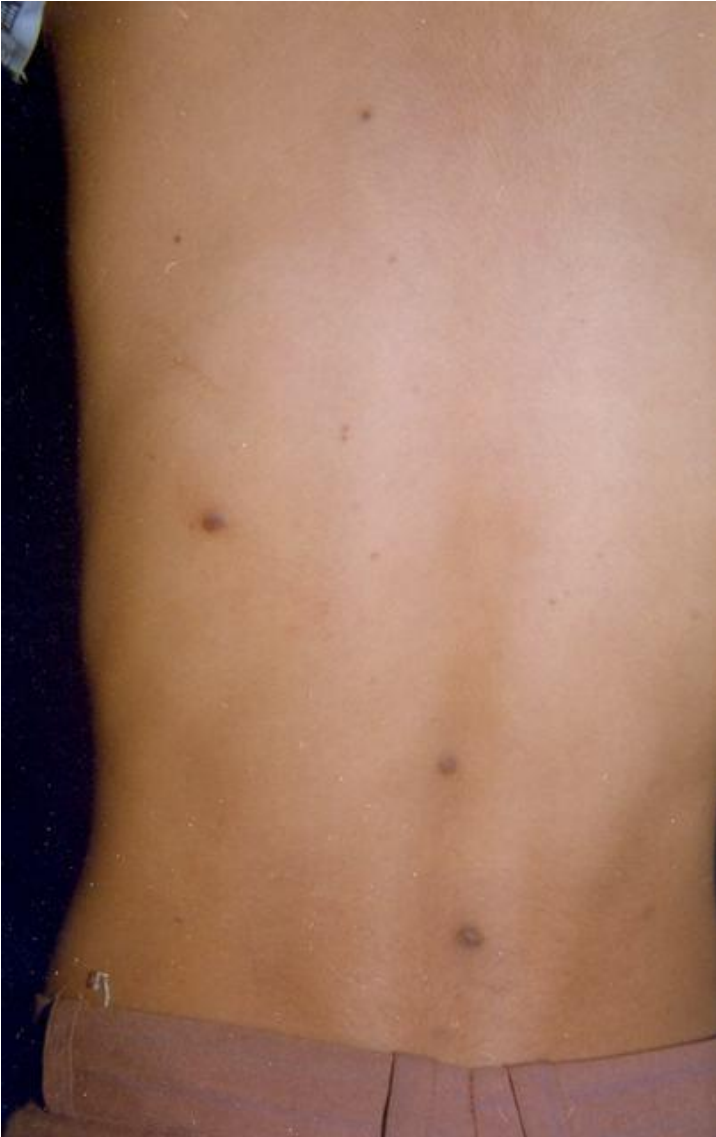Plantar Wart (Verrucae)



Verrucae (warts)

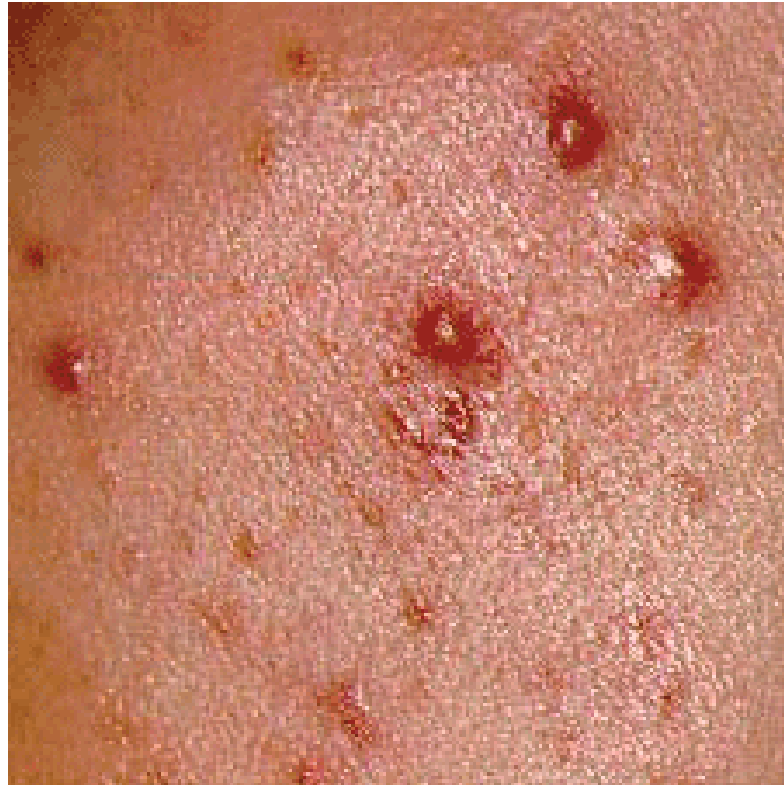- Viral infection of the skin.
- Removal by electricity, liquid nitrogen, acid, chemicals, or laser.

Macules



- Flat spots on the skin.
- Freckles.

Papules and Pustules

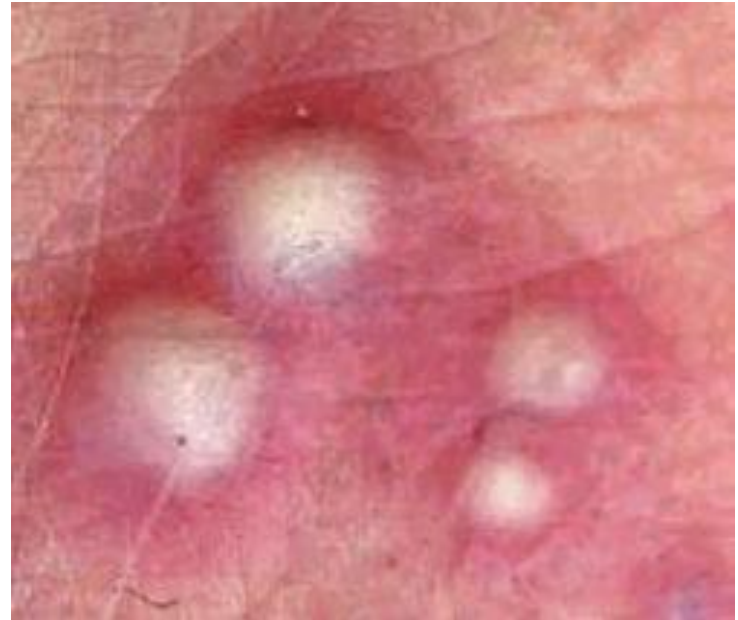

Papules

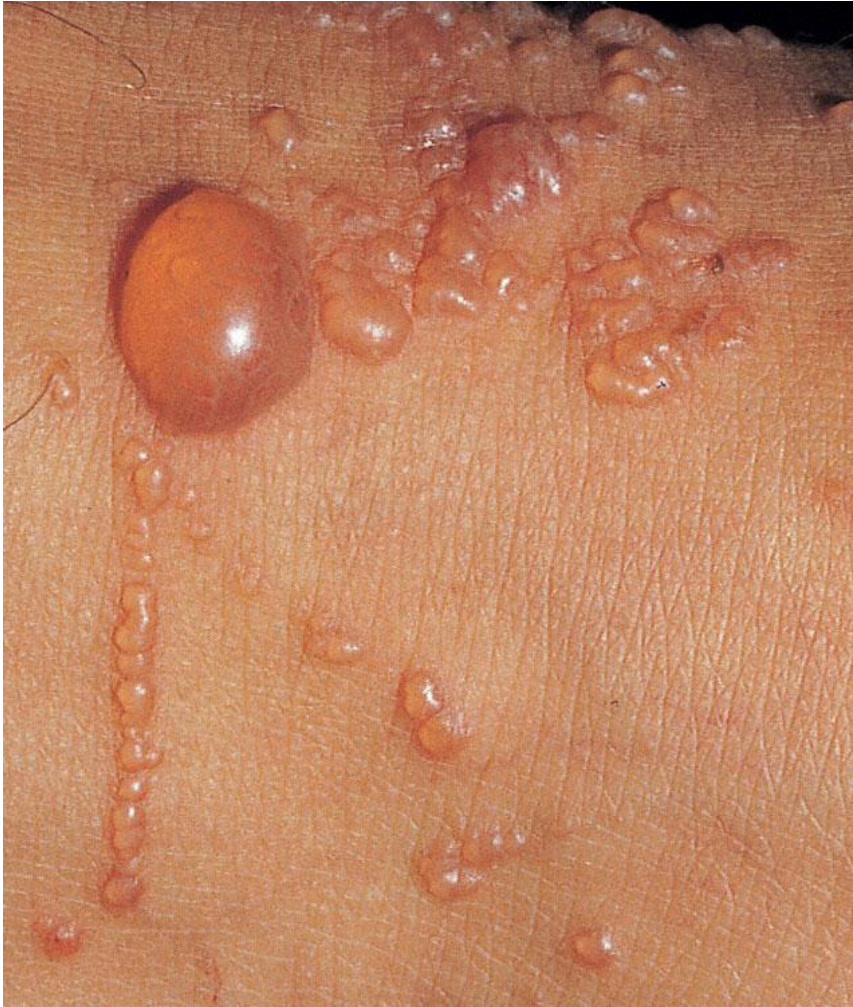
- Firm, raised areas such as pimples.
- Also, the eruptions seen in some stages of chickenpox and syphilis.

Pustules

- Pus-filled sacs.
- Acne, pimples.

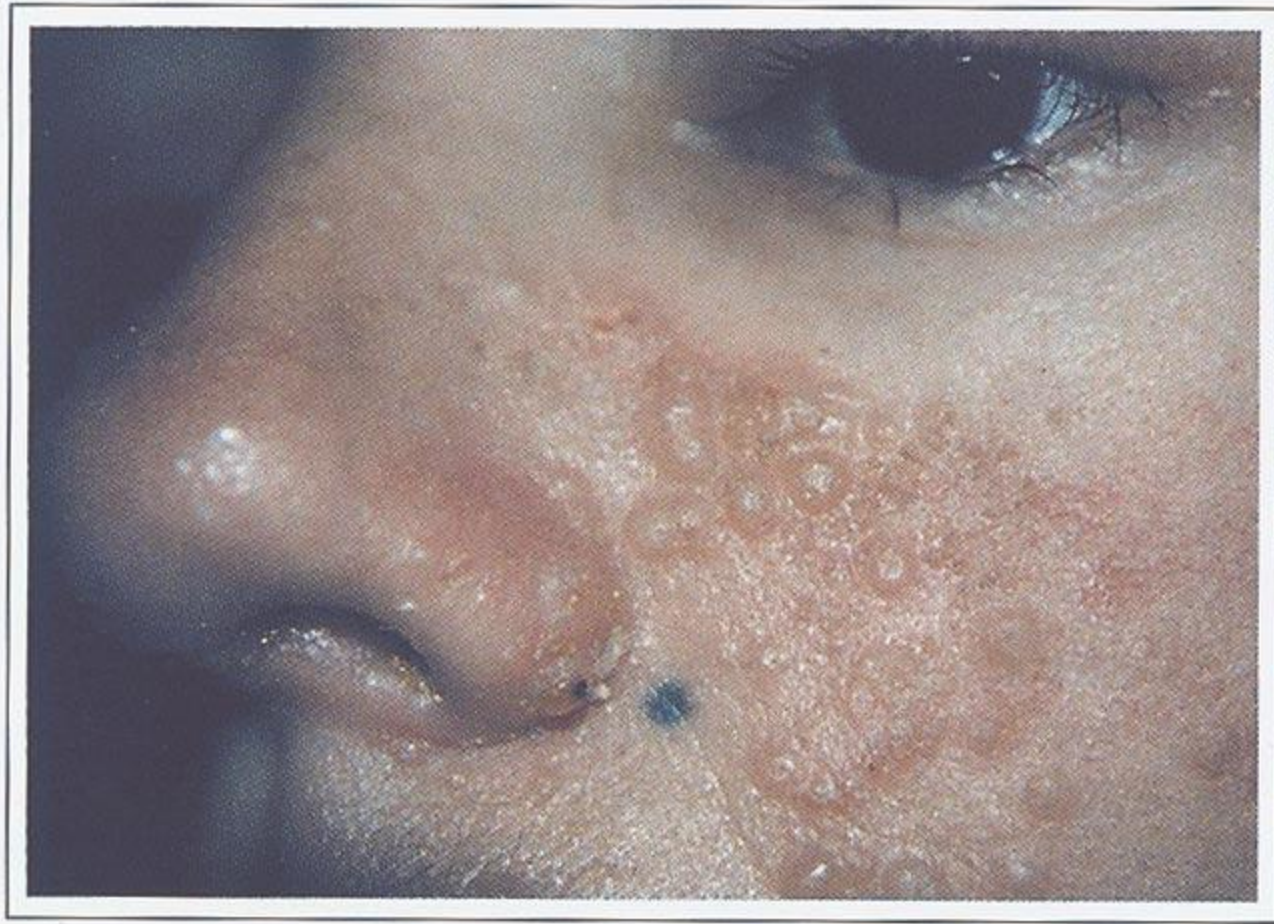

Vesicles



- Blisters or fluid filled sacs.
- Ex: chickenpox.

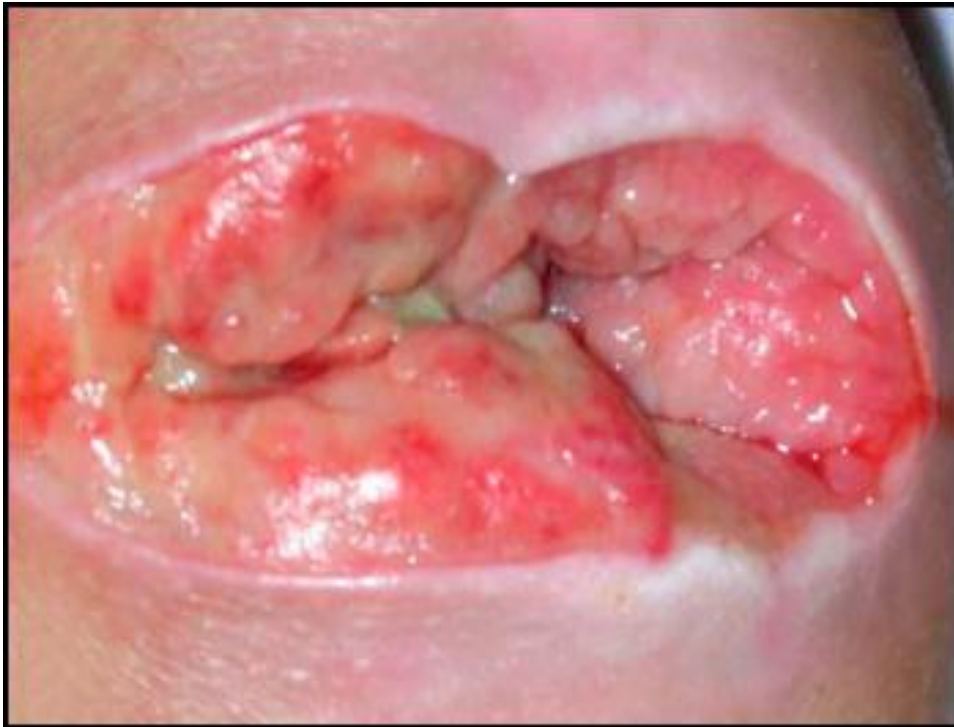Wheals



Wheals

- Itchy, elevated areas with an irregular shape.
- Hives, insect bites.

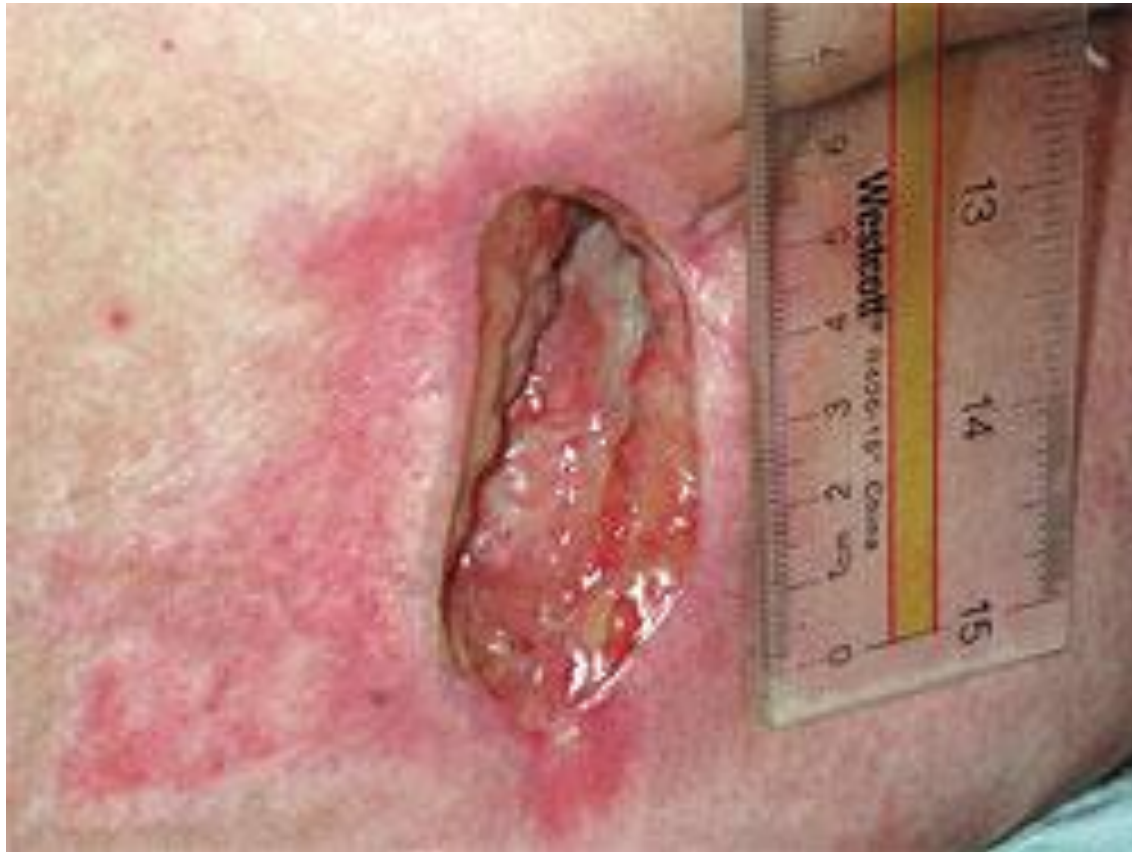Ulcer



Ulcer

- Deep loss of skin surface.
- May extend into the dermis.
- May cause periodic bleeding, formation of scars.
- Bedsores.

Another Ulcer



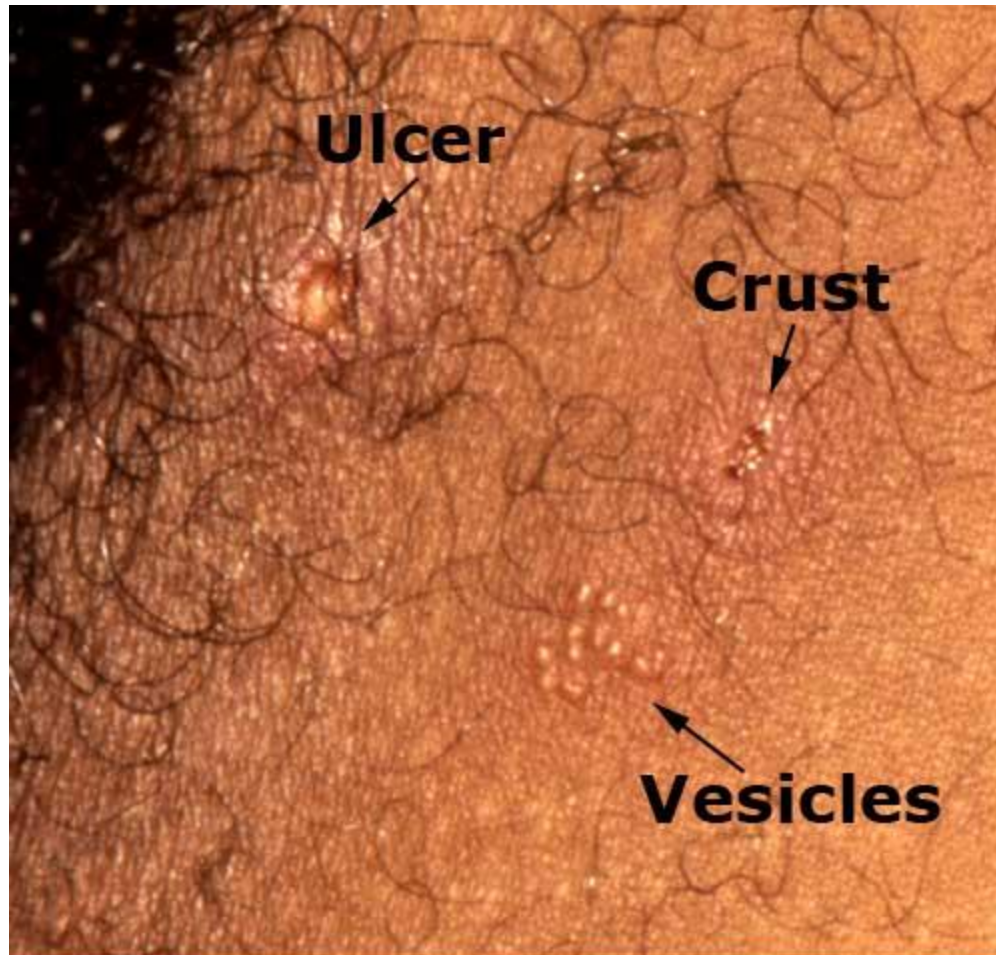


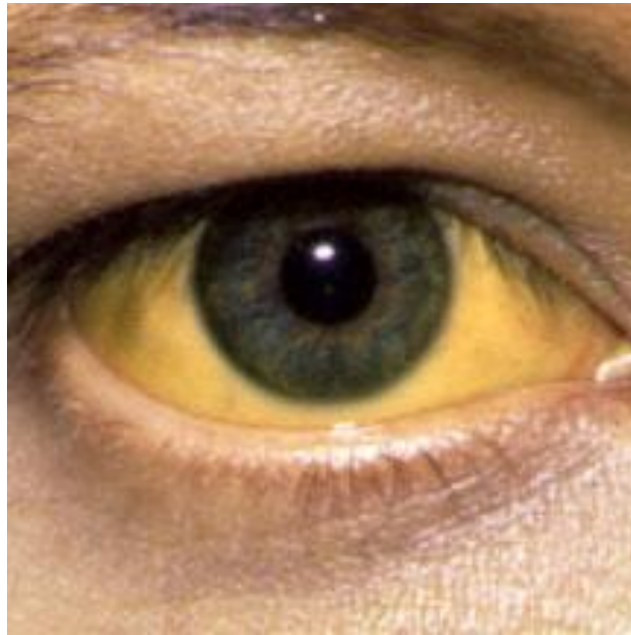
Photo courtesy of CDC - Dr. M.F. Rein & Susan Lindsley

Albino Skin Pigmentation



Person w/ absence of color pigmentation.

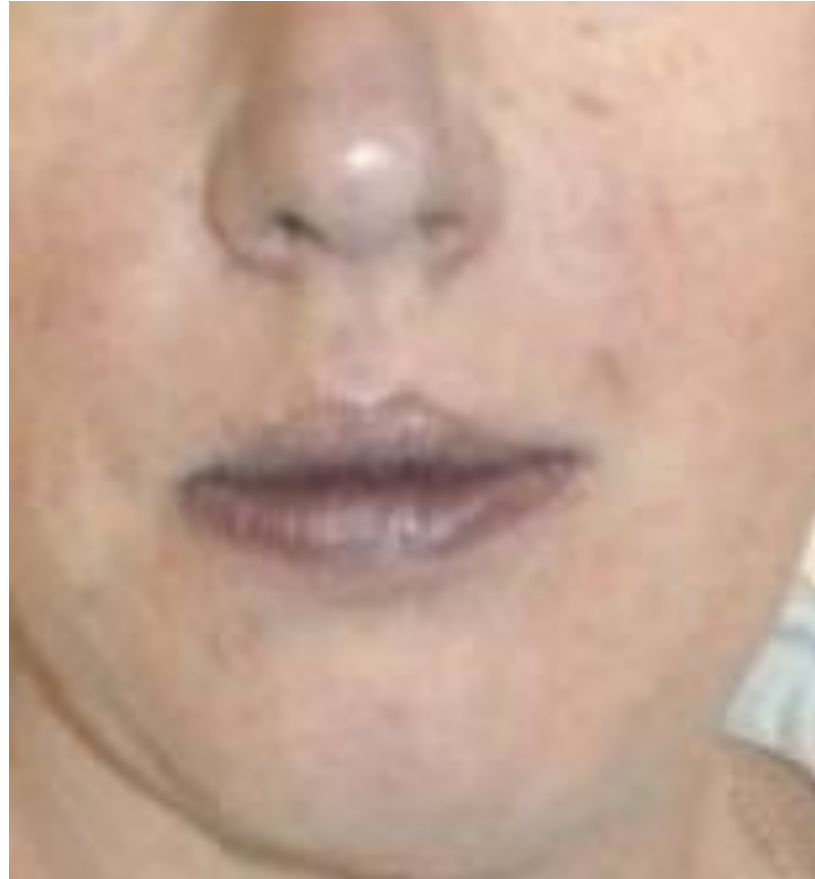Jaundice



Cyanosis



Cyanosis



Erythema

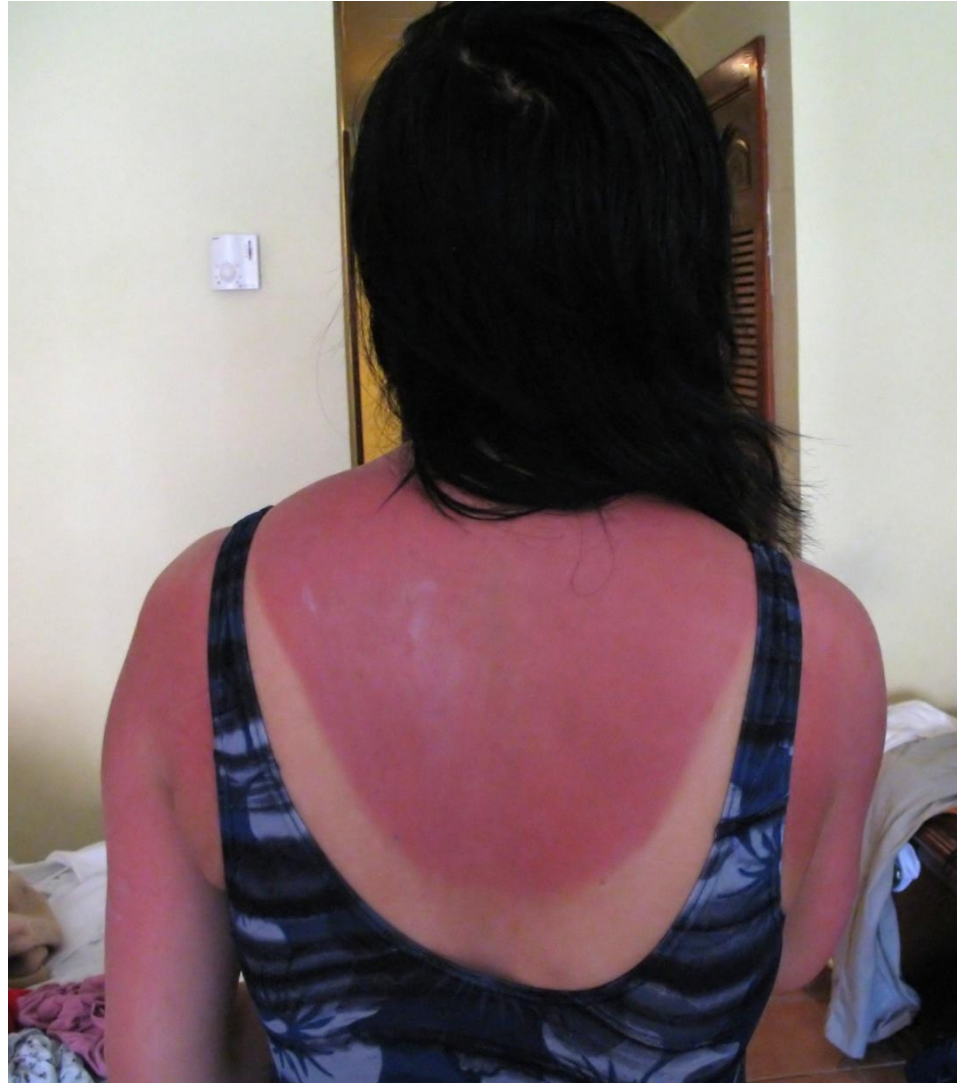

Red Color of Skin caused by hyperemia of the capillaries in the lower layer of skin.
AKA nervous Blushing

Burns

- First Degree
- Second Degree
- Third Degree

What degree burn is this?



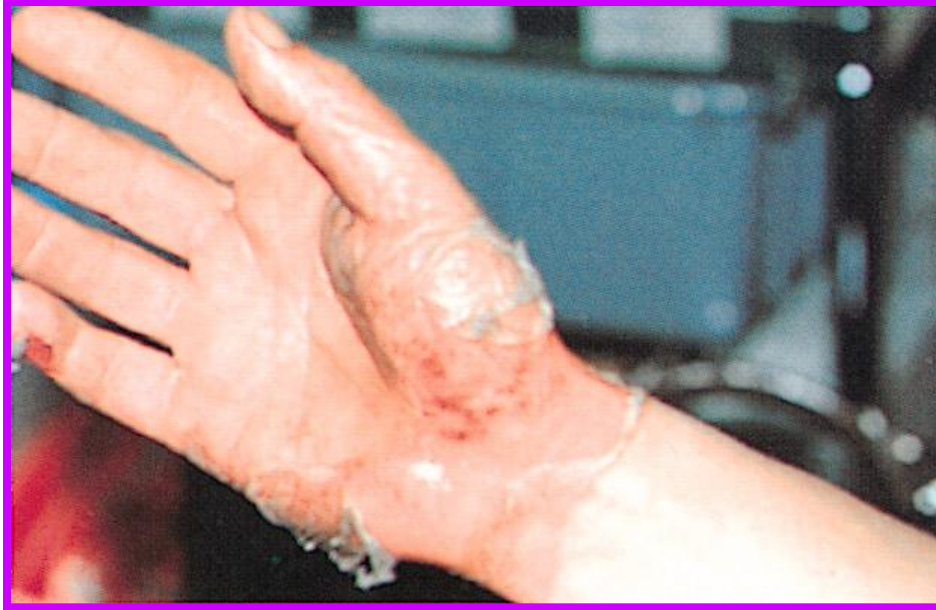First Degree Burn

Causes - extremely hot liquids, heated cookwear, sun.

Treatment - cool water, burn gel, cover with clean dressing.

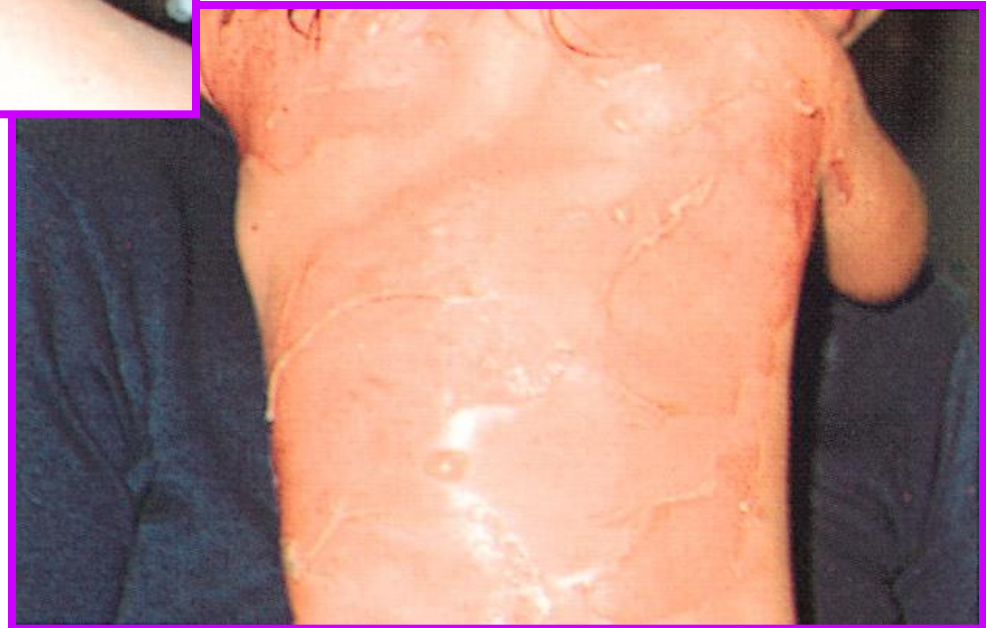Prevention - wear sun screen, be careful, pay attention.

Second Degree Burn

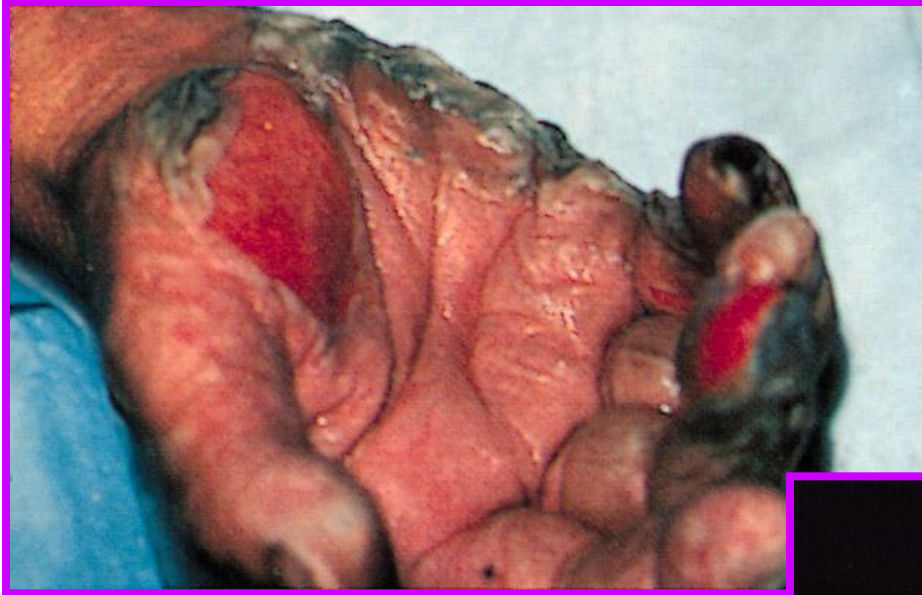

Causes- hot liquids,
extreme sun
exposure, fire,
heated cookwear.

Treatment- cool
water, cover with
clean dressing, **DO
NOT POP THE
BLISTERS!!**

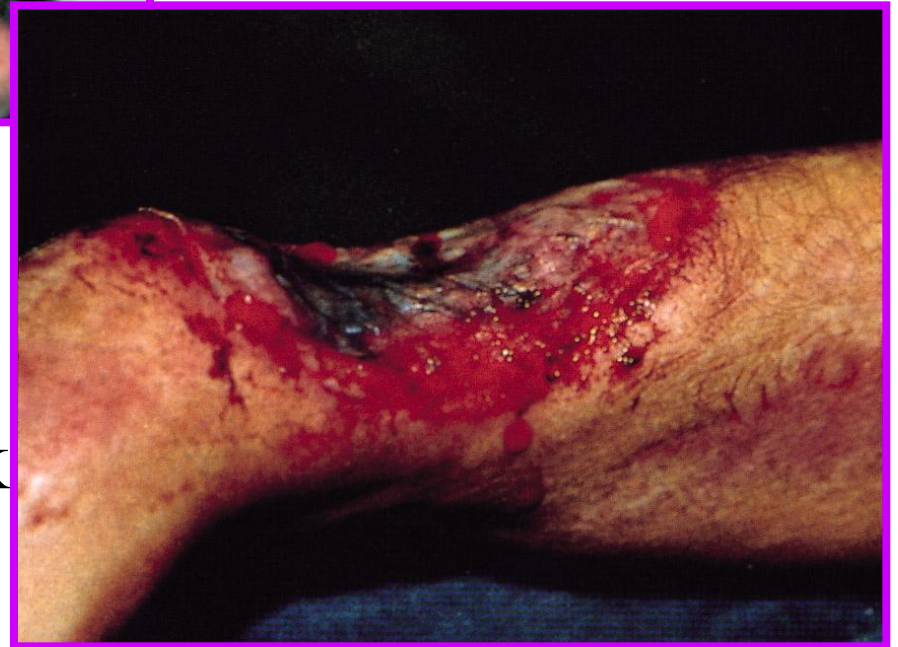

Third Degree Burn




Cause- Super hot liquids, fire, electricity

Treatment- loosely cover with dry sterile dressing, treat for shock immediately



True Emergency if...

- is due to chemicals or electricity.
- covers a significant area of the body.
- is to the face.



What NOT to do for burns:

- Don't use mayonnaise, butter, or ice!
- Don't put it in your mouth!
- Never pop blisters!
- Don't use burn gel on 3° burns!



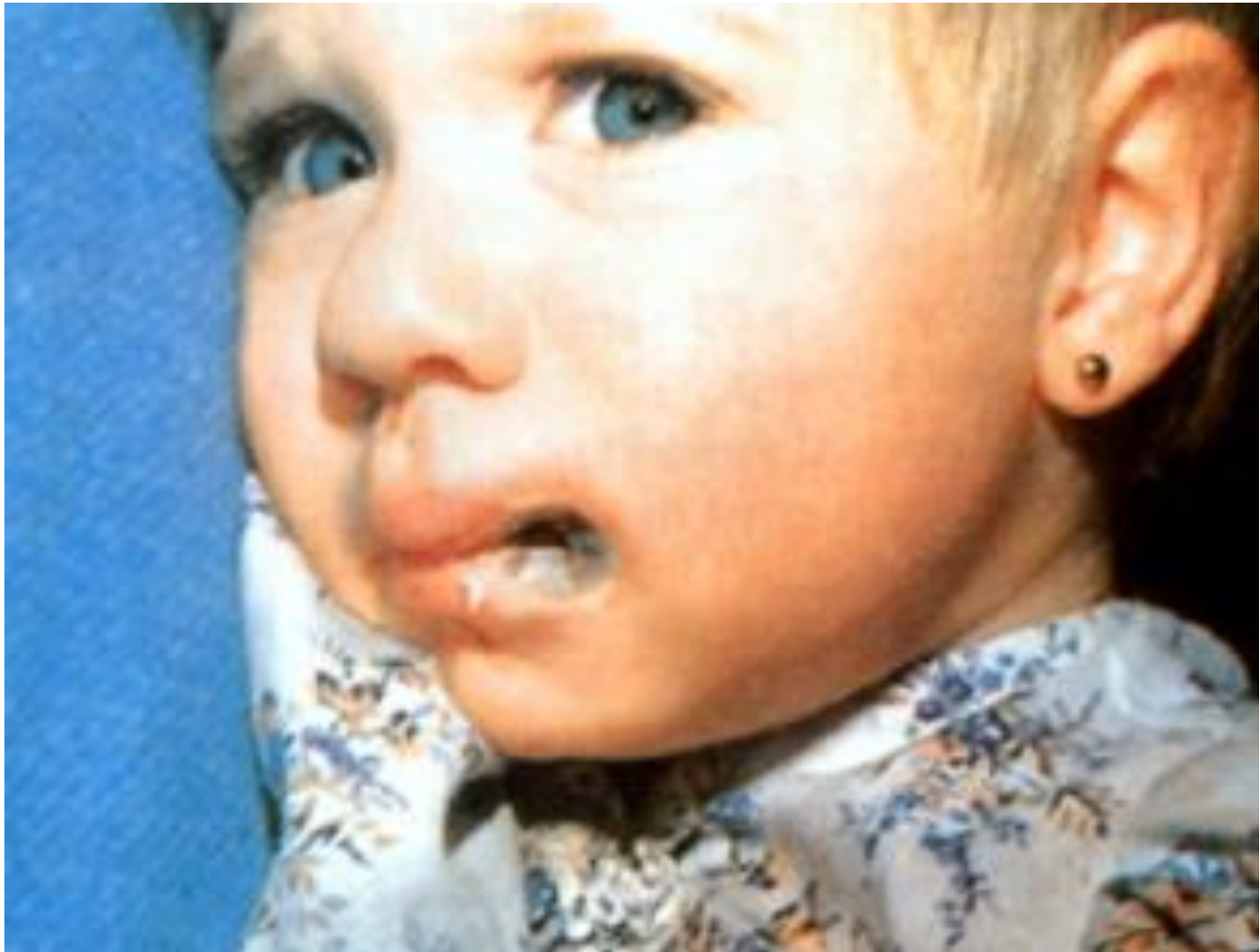What NOT to do for burns:

- Don't remove clothing or jewelry that is stuck to the burned area!
- Don't touch the burn with anything other than a clean covering!



Call 911 immediately if the burn:

- is due to chemicals or electricity.
- covers a significant area of the body.
- is to the face.



What caused this burn?



Chewing on Electrical Cord